

Lasers in Endodontics

Prof. dr. Norbert Gutknecht

*Aachen Research Institute for Lasers in Dentistry (AALZ), Clinic of Conservative Dentistry,
Periodontology and Preventive Dentistry, University Hospital of the RWTH, Aachen, Germany*

ABSTRACT:

This paper describes and discusses the use of the Nd:YAG and diode lasers in endodontics. Clinical studies clearly show advantages of laser treatments over currently-used conventional methods and techniques. The most important advantages are improved disinfection efficacy, more effective root canal cleaning, reduction of permeability, reduction of micro-leakage, and elimination of the need to use toxic solvents.

Key words: Nd:YAG, diode, endodontics, pulp, disinfection, root canal

INTRODUCTION

Endodontic therapy is a sequence of procedures aimed at eliminating pulp infection and protecting the tooth from future microbial invasion.

It consists of the following procedures:

- enlargement of the root canal
- removal of infected tissue
- disinfection of the root canal
- dense final filling

Conventional procedures use mechanical tools and toxic disinfection agents and have the following disadvantages:

- Debris removal and disinfection is usually very difficult due to complexity of the root canal system.
- On average, more than 30% of the canal's surface area remains covered by a smear layer, which protects bacteria in the dentinal tubules against intra-canal disinfection agents.
- Intra-canal medicines have a limited anti-bacterial spectrum and a limited ability to diffuse into the dentinal tubules.
- The conventional, mechanical removal of obturation materials is time-consuming.

The use of lasers in endodontic therapy has been extensively studied for the last 15 years. Laser treatments have been proven to have many advantages over conventional methods. Results suggest that the laser is an effective tool for the removal of debris, the smear layer and obturation materials, as well as being an effective disinfection tool.

LASER WAVELENGTH CONSIDERATION

The primary use of lasers in endodontics is focused on eradicating micro-organisms in the root channel, especially in the lateral dentinal tubuli. This requires a wavelength that shows high transmission through hydroxyapatite and water. Absorption curves show that Nd:YAG lasers, and in particular pulsed Nd:YAG lasers, are first-choice for this application. Nd:YAG lasers show the best results in transmission and micro-organism reduction measurements. Even at penetration depths exceeding 1.000 μm , 85 % reduction is achieved. The 810 nm diode laser is the second-choice laser source. Micro-biological studies have shown that this source provides the second highest micro-organism reduction, approximately 63%. This is nevertheless significantly lower than with Nd:YAG lasers. 980 nm diode lasers may also be an option although high transmission is achieved due to its higher absorption in water. This explains why this laser source, especially at a depth of 1.000 μm , can only achieve 30% to 40% micro-organism reduction.

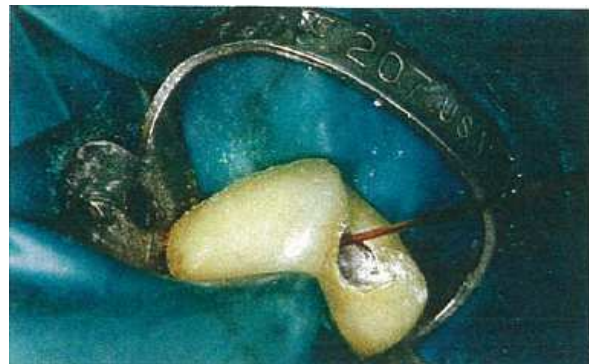

Fig. 1: Nd:YAG fiber inserted in the root canal of tooth 24

All other wavelengths, such as Er:YAG, Er,Cr:YSGG and CO₂ lasers, are less effective in deep dental tubulus disinfection. Their absorption in hydroxyapatite and water is so high that micro-organism reduction would predominantly only take place in the main canal, although reduction through thermal effects can still be detected in the lateral dentinal tubuli up to depths of 300 μm to 400 μm . Er:YAG and Er,Cr:YSGG lasers can however be successfully used to remove organic tissue and smear layers. SEM photography (see Fig.2) of the laser-treated root canal walls reveals clean

surfaces, free of smear layer and debris.




Fig.2: Surface Electron Microscope (SEM) photo of dentine cleaned by Er:YAG laser.

THERMAL CONSIDERATION

BEHRENS and GUTKNECHT, 1993, conducted in-vitro experiments on dentine slices with laser power settings that take into account even the most extreme situations, in order to determine that no thermal damage occurs in pulsed Nd:YAG laser or diode laser treatments. When measuring the root surface, a temperature of 38 °C was obtained after a 45-second treatment duration at 15Hz/1.5W. This value lies within the physiological area. It must be considered that in an in-vivo situation the dental tissue is more efficiently cooled by the blood flow that surrounds the root surface.

The high temperatures in the apical area of the root, as visualized by the Finite Elements model of GUTKNECHT et al., 1995, and JUTTEN et al., 1995, indicate that micro-organisms in the root branches are destroyed.

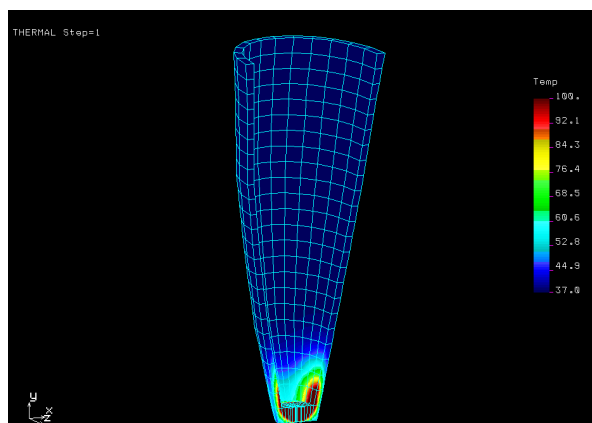


Fig. 3: Detail from the Finite Elements model. Demonstration of the course of temperature in the apical third.

The temperature on the root canal wall rapidly decreases as the treatment with the fiber-optical

waveguide is continued in the coronal direction. This guarantees that the surrounding tissue is only marginally affected and thus damage should not be expected.

MORPHOLOGICAL CHANGES

The smear layer is completely removed and the dental tubuli are, for the most part closed through inorganic melting if the Nd:YAG laser is applied with 15Hz/1.5W settings, (GUTKNECHT, 1991). Similar results can be expected if the 810 nm laser diode is used.

If the Er:YAG laser is applied, the smear layer will be completely removed and the dental tubuli remain open.

DISINFECTION EFFECT

The bactericidal effect of conventional alternating rinsing in the root canal preparation with H₂O₂/NaOCl is proven (BYSTRÖM et al., 1985; ORSTAVIK et al., 1990; SHIH et al., 1970; SMITH et al., 1986; SPANGBERG et al., 1973). However, the extent of the micro-organism reducing effect varies from study to study. BYSTRÖM et al., 1983, were only able to observe an 80 % bacterial reduction after five treatment sessions. While in addition, these effects can only be achieved with root canals of up to ISO 30, and not with curved roots.

GUTKNECHT et al., 1996, achieved an average of 99.92 % bacterial reduction in the root canal using the Nd:YAG laser with standard settings of 15 Hz at 100 mJ = 1.5 W, repeated four times for 5 to 8 sec. In 1994, ROONEY et al., and HARDEE et al., described reductions of 99 % when using a Nd:YAG laser in different experimental designs and bacterial combinations.

Further studies examined the depth effect of the laser in the root canal dentine. In 1997, KLINKE et al., were able to prove a bactericidal effect of the Nd:YAG laser at a depth of 1,000 µm. In comparison, a rinsing solution, such as NaOCl, only achieves effective bacterial reduction up to a depth of 100 µm (ORSTAVIK et al., 1990).

CLINICAL PROCEDURE

The sum of all pre-clinical studies of laser-supported endodontic treatments has been the foundation for the development of a laser-supported endodontic therapeutic plan. Based on their specific bactericidal effect, laser procedures have been integrated in the conventional endodontic therapeutic concept to indisputably improve conventional therapy. Clinical studies have led to the further establishment of a laser-

supported therapeutic plan and have allowed results to be verified over defined periods of time in order to enable statements to be made about the success prospects of laser-supported endodontic treatments.

In 1996, GUTKNECHT et al., reported as a significant fact that only 21 % of problematic cases were able to be treated with success without laser support, while 82 % of cases were successfully resolved with Nd:YAG laser support, after having been unsuccessfully treated beforehand with conventional methods (medicinal inlays, corticoids, CHKM, different rinsing solutions and preparations, etc.). Based on their clinical experience and patient follow-up results, the authors further observed that the micro-organism reduction, which is decisive for therapeutic success must be clearly attributed to the laser. The above reported statistics must be evaluated as an important result when viewed in relation to the complex initial pathological situation and the strict selectivity that applies to cases.

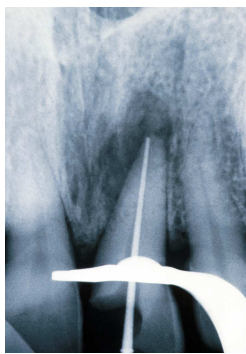


Fig. 4: Initial findings on a female patient who had been unsuccessfully treated for over six months. Situation after the laser treatment – Masterpoint picture.

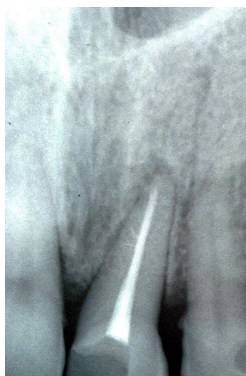

Fig. 5: Follow-up six months after the laser treatment. The female patient is absolutely symptom-free.

It was furthermore reported that damage to the optical fibers was extremely rare (< 0.5%), and in none of the cases did this lead to a treatment failure.

The probability of a preparation instrument fracturing is markedly higher (3 to 4%). Another positive aspect of the laser treatments is that it is possible to even treat strongly curved root canals and those that are only able to be prepared up to ISO 30. The released laser energy still has positive micro-organism reducing effect in the dentine layers adjacent to the canal lumen and in the peri-apical region. In contrast, rinsing solutions used in conventional disinfection have no or only slight effects in such small lumina, owing to their physical limitations. This is especially applicable to the endodontic problem regions of the apical third.

In practice, little additional time is needed for a laser treatment. Patients' acceptance however, is very high because of the possibility to save the tooth. 40 % of the test cases were conducted between 1991 and 1992; we can therefore assume that these positive statements also apply to the medium/long term post-treatment period.

Applications

The obtained diagnosis, after anamnesis and clinical and radiological examination, forms the basis for our clinical procedure. The inflammatorily damaged tissue can be removed by means of vital extirpation if a bacterial infection of the crowns or root pulp, including any related consequences, has not yet taken place. However, the situation is quite different when a strong bacterial infection of the endodontic system is diagnosed after anamnesis and, clinical and radiological examination. We then speak of gangrenous changes in the endodontic system in which, owing to the special ecological conditions that apply, specific species are present that evoke the picture of peri-apical periodontitis (SUNDQIST, 1993; PEREZ et al., 1993). The desired therapy consists of eliminating the pathogenic organisms as much as possible, and as a result completely curing the inflammation, avoiding reinfection and stimulating osteoanagenesis (SUNDQIST, 1993; PEREZ et al., 1993; BYTRÖM et al., 1989; OGUNTELEI, 1994). According to LEHNERT, 1993, only very uncertain or no prospects of success can be given for the conventional therapy of gangrenous teeth. Besides bacterial colonization of the root canal with a species spectrum, anatomic conditions like strongly curved, partially obliterated root canals and strong ramifications in the apical third of the root canal can strongly restrict therapeutic success. The result of this is the challenge for endodontics practitioners that first of all, non-invasive and thus more pleasant methods for the patient should be pursued before surgical intervention (LEHNERT, 1993, SMITH et al., 1993, TETSCH, 1986, WASSMUND, 1935, MAALOUF et al., 1994, ALLEN et al., 1989).

There is a need, under these circumstances, for a therapeutic device that is able to effectively combat the cause of the disease, i.e. bacterial colonization.

Indications and contra-indications for laser-supported endodontic treatments

Laser-supported treatments should be favored when treating patients that show one or several of the following symptoms:

- Teeth with a purulent pulpitis or pulp necrosis
- Teeth, of which the crown and root pulp show gangrenous changes
- Teeth with peri-apical lesions (peri-apical gap from 1 mm, up to granulomas with a diameter of 5 mm and more) (Smith et al., 1993, Kovacs et al., 1993, Schroeder, 1983)
- Teeth with a peri-apical abscess
- Teeth with lateral canals that lead to periodontal involvement
- Absorption of the apex caused by inflammation or trauma
- Teeth that have been treated for at least three months without success (with alternating rinsing and medicinal inlays)

Before starting the treatment it must be established whether the tooth in question is worth conserving for functional, prosthetic or aesthetic reasons, that a tooth with a destroyed crown and root caries can be reconstructed, that the patient is interested in dental conservation and that the patient's health condition enables the endodontic treatment to be performed (exclusion of a focal process).

Clear contra-indications for performing a laser-supported endodontic treatment are very advanced periodontitis (degree 3 looseness), a deep crown or root fracture on the to-be-treated tooth, and when obliterated root canals are diagnosed on the endodontically affected tooth.

Procedure

Patients ought to be recorded in a standardized manner by means of an inquiry sheet, before, during and after treatment. An X-ray picture of the tooth requiring treatment should be made in order to clearly capture the initial situation after the anamnesis and clinical examinations. Based on the X-ray measuring picture, the root canals of the molars should now be prepared to a size of at least ISO 30, and the root canals of all the remaining tooth groups as far as medically necessary (fine dentine chips) and

anatomically possible. A standardized physiological salt solution is used as a rinsing medium. The canals are dried with sterile paper tips.

The length of the root canal, obtained through the X-ray measuring picture, is transferred exactly to the fiber-optical waveguide to ensure that the flexible 200µm optical fiber reaches the physiological apex. The fiber is introduced into the root canal to the apex without activating the laser. Only then is the laser activated, and the fiber guided in an apical to coronal direction with rotary movements and in contact with the root canal wall. The root canals are filled *lege artis* after the third session at the latest (AH 26 and Guttapercha, lateral condensation) (KEREKES et al., 1979).

Radiological documentation takes place both before (initial findings – X-ray measurement) and after having completed the endodontic treatment (filled root canal). The patients should have a follow-up visit once a year and be radiologically documented.

The criteria for a successful treatment are defined as follows:

- Symptom-free from the end of the treatment onwards, until the last follow-up examination (percussion negative, occlusion without problems).
- No need for surgical interventions (extraction or apicectomy).
- Objective reduction of the apical translucency after three to twelve months (X-ray comparison).

CONCLUSION

A review of studies in the field of laser use in endodontics clearly shows that Nd:YAG laser treatments may effectively replace conventional techniques. Especially its improved disinfection efficacy, more effective root canal cleaning, reduction of permeability, reduction of micro-leakage, and elimination of the need to use toxic solvents represent the main advantages for patients and dentists.

REFERENCE

1. Proceedings of the 1st International Workshop of Evidence Based Dentistry on Lasers in Dentistry, Quintessence Publishing, 2007, ISBN 978-1-85097-167-2



**Prof. Dr. Norbert
Gutknecht**

Since 1992, Prof. Dr. Norbert Gutknecht has been the head of the Aachen Research Institute for Lasers in Dentistry (AALZ) at the Clinic of Conservative Dentistry, Periodontology and Preventive Dentistry at the University Hospital of the RWTH in Aachen, Germany. He is co-founder and president of the German Society for Laser Dentistry (DGL) and Organizing Chairman of the International Society for Lasers in Dentistry - ISLD. As Editor of the Laser in Medical Science Journal and as a visiting Professor at the University of Nice and Sao Paulo, he is an established expert in Laser Dentistry. His national and international workshops on indications and treatment expectations in laser-based dental therapy are widely visited.